

# MJEM

MEDITERRANEAN JOURNAL OF EMERGENCY MEDICINE

## Original Articles

Heat exhaustion in the emergency department should not be confused with other forms of heat related illness

Influential factors on urban and rural response times for emergency ambulances in Qatar

EPP suite à l'actualisation du protocole de prise en charge des syndromes coronariens avec sus décalage du segment ST adapté à un département rural

## Case Reports

Sweet syndrome presents with severe SIRS

A Scottish shower

Reducing the trauma burden in the UAE

Successful extracorporeal membrane oxygenation use in acute respiratory distress syndrome after freshwater drowning

Utility of PoCUS in diagnosis of aortic dissection

Cannabinoid Hyperemesis Syndrome with hyperlactatemia

Envenimation. Prise en charge d'une morsure de vipère au retour du Mali

Un syndrome douloureux lombo-abdominal atypique

# SUCCESSFUL EXTRACORPOREAL MEMBRANE OXYGENATION USE IN ACUTE RESPIRATORY DISTRESS SYNDROME AFTER FRESHWATER DROWNING

NGUYEN TV, CHECINSKI A, ROLLIN N, LEFORT H, TAZAROURTE K. Successful extracorporeal membrane oxygenation use in acute respiratory distress syndrome after freshwater drowning. *Med Emergency, MJEM* 2018; 26:29-31.

**Key words:** acute respiratory distress syndrome, drowning, ECMO, extracorporeal membrane oxygenation, mobile unit of cardiac assistance, out of hospital

## ABSTRACT

Drowning incidents involve two million people each year, mostly children and young adults, and lead to 400,000 deaths worldwide. Acute respiratory distress syndrome (ARDS) is the leading cause of death in the patients that are successfully rescued. Whereas the literature on the use of cardiac bypass for rewarming hypothermic patients in cardiac arrest (CA) after drowning is abundant, evidence on the use of extra corporeal membrane oxygenation (ECMO) for the treatment of ARDS secondary to water aspiration is scarce. We report the case of a patient who was rescued in CA after a drowning attempt and presented with a refractory ARDS after return of spontaneous circulation, successfully treated with ECMO.

### Authors' affiliation:

**Correspondent author: Hugues LEFORT, MD**

Senior practitioner in emergency medicine of the French Military Health Service  
Head, Emergency Department, Hôpital d'instruction des armées Legouest  
27 avenue de Plantières, BP90 001 - 57 077 Metz Cedex 03, France  
hdlefort@gmail.com

**Nguyen TV, MD<sup>1</sup>, Checinski A, MD, MSc<sup>1</sup>, Rollin N, MD<sup>2</sup>, Lefort H, MD<sup>3</sup>, Tazarourte K, MD, PhD<sup>4</sup>**

1. Pôle Urgence-Réanimation Polyvalente-SAMU 77, Hôpital Marc Jacquet, 77000 Melun, France
2. Pôle Anesthésie-réanimation-USC, Hôpital Jean-Verdier, 93140 Bondy, France
3. Structures des urgences, Hôpital d'instruction des armées Legouest, 57000 Metz, France
4. Pôle Urgence-Réanimation médicale-Anesthésie-Réanimation-SAMU 69, Hôpital Edouard Herriot, 69000 Lyon, France

### Article history / info:

Category: Case report  
Received: Feb. 1, 2017  
Revised: Mar. 1, 2017  
Accepted: May 15, 2017

### Conflict of interest statement:

There is no conflict of interest to declare



Dr Tueng-Vi Nguyen

## INTRODUCTION

Worldwide, two million people, mostly children and young adults, are hospitalized each year after a drowning incident and 400,000 die [1]. Sudden hypoxia, leading to unconsciousness and cardiac arrest, is the leading cause of immediate death. In hospitalized victims, acute respiratory distress syndrome (ARDS) secondary to water aspiration is the leading cause of death [2]. However, there are few data about the use of extracorporeal membrane oxygenation in those patients. In this article we report the case of a patient who was successfully rescued with extracorporeal membrane oxygenation (ECMO) from a refractory ARDS after a drowning incident.

## CASE REPORT

A 30 year old male, attempted to kill himself by jumping in a river from a bridge. The victim was spotted by a fire brigade vehicle passing by this bridge, while jumping over the rail. The fire brigade after alerting Emergency Medical Service attempted rescue.

The victim was taken out of water approximately 1000 meters further away from the bridge, after five minutes of exposition to cold freshwater, in cardiac arrest. Basic life support was initiated by the fire brigade and spontaneous cardiac activity was restored after two minutes of cardiopulmonary resuscitation.

Upon arrival of the Emergency Medical Team (EMT), the patient was unconscious with an initial Glasgow Coma Scale (GCS) at 6 (**Figure 1**). He was spontaneously breathing with 15 L.min<sup>-1</sup> O<sub>2</sub> supply provided by a non-rebreather mask. Blood pressure was 150/100 mmHg and heart rate 83 pulses per min. Surface temperature was 31°C and oxygen saturation was unreadable. He rapidly became agitated and had an abundant pink frothy sputum expectoration. He was intubated in rapid sequence, and mechanically ventilated in an assisted control ventilation mode with a Tidal volume (Vt) = 500 mL, a fraction of inspired oxygen (FiO<sub>2</sub>) = 1 and a positive end-expiratory pressure (PEEP) = 5 cmH<sub>2</sub>O. Upon instauration of invasive mechanical ventilation the O<sub>2</sub> saturation reached 86%. Shortly afterwards a lung protective ventilation was started with a Vt of 6 mL.kg<sup>-1</sup> of estimated body weight and PEEP was increased to 10 cmH<sub>2</sub>O. Those settings improved gas exchange, and saturation reached 94%.

The patient was transferred in our Intensive Care Unit for further management. Upon arrival in intensive care the patient's condition worsened, with circulatory and respiratory failure. Mean arterial pressure (MAP) was below 65 mmHg despite volume expansion and, arterial blood gases with FiO<sub>2</sub> = 100% and PEEP = 10 cmH<sub>2</sub>O showed a combined acidosis with severe hypoxemia (pH = 7.12, PCO<sub>2</sub> = 52 mmHg, PO<sub>2</sub> = 38 mmHg, HCO<sub>3</sub><sup>-</sup> = 16.9 mmol.L<sup>-1</sup>, lactate = 6.2 mmol.L<sup>-1</sup>). Central body temperature was 35°C, without abnormalities on the ECG. Echocardiography was only possible in subcostal view and showed visually conserved left ventricular ejection fraction and signs of low right atrial filling pressures. However it was impossible to get a workable apical and parasternal views. This was later explained by chest radiography findings (**Figure 2**); which revealed bilateral lung infiltrates and a small pneumomediastinum. Noradrenaline was started and rapidly increased up to 2 mg.h<sup>-1</sup> and volume expansion was continued under echocardiographic control. The patient was deeply sedated and paralysed with atracium. Ventilatory settings were altered. In particular PEEP was increased, in accordance with the ARDS net protocol. These therapeutic



**Figure 1:** Case management of a drowned person in Seine river waiting for ECMO at prehospital level ©SSA\HLefort

interventions restored hemodynamics, decreased lactic acidosis and hypercarbia. However oxygen levels remained low with a PO<sub>2</sub>/FiO<sub>2</sub> ratio of 41, supporting the diagnosis of refractory ARDS.

We decided to treat the patient with ECMO. This technique doesn't exist in our hospital; therefore a mobile unit of cardiac assistance (MUCA) was requested. While waiting for the MUCA the patient was placed in prone position. The MUCA arrived two hours after request and the patient was implanted with a percutaneous veno-venous ECMO. The venous cannula was inserted through the left femoral vein and positioned in the inferior vena cava and the arterial cannula was inserted through the left internal jugular vein and positioned in the right atrium. Patient's oxygenation rapidly improved upon ECMO start. Output was set at 5 L.min<sup>-1</sup> and oxygen was rapidly decreased to 21%. Ventilator settings were altered to a Vt of 160 mL and a PEEP of 16 cmH<sub>2</sub>O. The patient was subsequently transferred by our EMT to the intensive care unit of the tertiary hospital that provided the ECMO, as is standard protocol in such cases.

The patient's condition rapidly improved after ECMO initiation. He was hemodynamically stable and his pneumomediastinum was never a concern. By day three, he was weaned of ECMO and extubated by day five. He showed no sign of neurological impairment. However he was agitated and delirious. It was then discovered that the patient had a past medical history of psychosis and had discontinued his treatment when he attempted to kill himself. Therefore, he was discharged to the psychiatric ward for further treatment on day seven.

## DISCUSSION

Drowning is a well-known purveyor of ARDS patients [3]. Pathophysiology of lung injury in cases of freshwater aspiration involves a mechanic insult with surfactant alteration that results in alveolar collapse and edema, ventilation to perfusion ratio mismatch and lung compliance decrease, resulting in profound hypoxia [1]. Thus we chose an open lung strategy (low tidal volume and higher PEEP) [4] to ventilate the patient, in addition to neuromuscular blocking agents and prone positioning, as is recommended in ARDS [3]. However despite those treatments the patient developed refractory ARDS and required a rescue therapy.

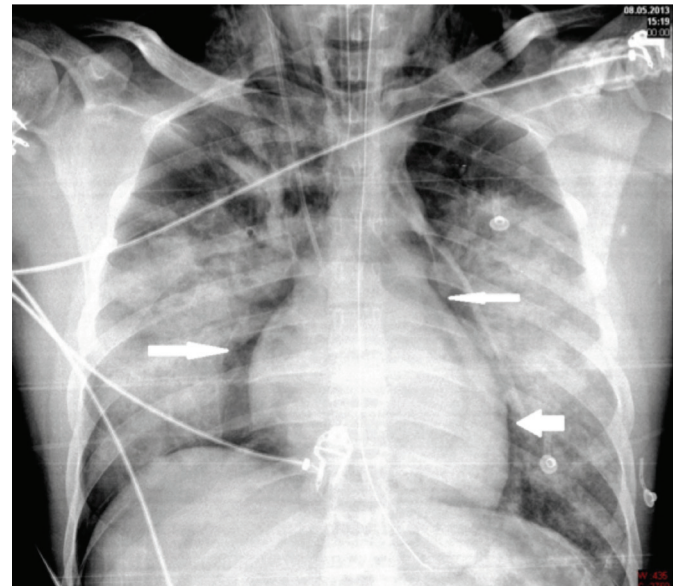
Exogenous surfactant therapy has been proposed in refractory hypoxia due to freshwater aspiration [5]. However, this strategy has never been evaluated in clinical trials, and is not recommended [6]. Nitric oxide is unavailable on our site, thus the last resort for the patient was extra corporeal life support (ECLS). Briefly ECLS, mainly cardiopulmonary bypass (CBP), has been developed to support open heart surgery. Technologic progress in ECLS devices and development of ECMO during the past 20 years has enabled new application of this technique, outside of theatres, for prolonged organ support (i.e. treatment of cardiac and pulmonary refractory failure). Furthermore, implantation of ECMO in secondary care hospitals and transfer to referral centers has been made possible by the recent development of portable devices.

However data on the benefits of ECMO in ARDS are still conflicting, although the results of the CESAR trial [7] seem to show an improvement in survival rates. Thus ECMO is not recommended by the guidelines of the surviving sepsis campaign [8].

There are some reports on the use of CPB in drowned patients. However this technique was mainly used for rewarming purposes in prolonged cardiac arrests [9]. In this study, patients were rewarmed by cardiopulmonary bypass (CPB) until return of spontaneous circulation. ECMO was only used in two patients with severe lung edema after CPB termination.

There is scant evidence on the implantation of ECMO in refractory ARDS after drowning without cardiac arrest. In most cases, ARDS had a delayed onset [10], enabling transfer to a referral centre and initiation of ECMO. However in our patient, refractory hypoxemia was reached within one hour and, at this point he could not be safely transferred. Thus he required the intervention of a MUCA. In France, MUCA were first created to provide circulatory support to patients in cardiogenic shock in remote hospitals, using veno-arterial ECMO. After implantation they were transferred to referral centers [11]. Due to the success of this strategy, the scope of MUCA was expanded to refractory ARDS, within a yet unfinished multicentre clinical trial (EOLIA trial).

We found one case report of a patient who had an acute onset of refractory ARDS [5]. However in this case the patient was first transferred to a centre with CPB capabilities by rotary wing air medical crew prior to ECMO implantation. Our institution doesn't have ECMO capabilities per se, however they can be provided rapidly by the MUCA if needed. Our patient was implanted with a veno-venous ECMO within two hours of request. Hypoxemia was corrected within minutes. After transfer to the referral centre, his lungs recovered rapidly within three days allowing fast ECMO weaning. Mostly we think that this



**Figure 2:** Postero-anterior chest radiography showing air outlining mediastinal structures on both sides of mediastinum (Arrows) ©ACHecinsky

rapid recovery is due to the lack of severe aspiration pneumonia as opposed to previously described cases [9].

## CONCLUSION

Refractory ARDS in drowned patients is a potentially lethal condition. ECMO or ECLS are not techniques that are available in every centre. However our case report demonstrates that the development of mobile units of cardiac assistance can provide this rescue therapy to patients admitted to local hospitals after drowning, with positive outcome. However, in most cases, prognosis of drowned patients is governed by the post resuscitation syndrome after cardiac arrest and hypoxic encephalopathy.

## REFERENCES

1. Layon AJ, Modell JH. Drowning: Update 2009. *Anesthesiology* 2009; 110:1390-401.
2. Salomez F, Vincent J-L. Drowning: a review of epidemiology, pathophysiology, treatment and prevention. *Resuscitation* 2004; 63:261-8.
3. Fanelli V, Vlachou A, Ghannadian S, Simonetti U, Slutsky AS, Zhang H. Acute respiratory distress syndrome: new definition, current and future therapeutic options. *J Thorac Dis* 2013; 5:326-34.
4. Briel M, Meade M, Mercat A, Brower RG, Talmor D, Walter SD, et al. Higher vs lower positive end-expiratory pressure in patients with acute lung injury and acute respiratory distress syndrome: systematic review and meta-analysis. *JAMA* 2010; 303:865-73.
5. Diamond W, MacDonald RD. Submersion and early-onset acute respiratory distress syndrome: a case report. *Prehospital Emerg Care*. 2011; 15:288-93.
6. Walsh BK, Daigle B, DiBlasi RM, Restrepo RD; American Association for Respiratory Care. Clinical Practice Guideline. Surfactant replacement therapy: 2013. *Respir Care* 2013; 58:367-75.
7. Peek GJ, Mugford M, Tiruvoipati R, Wilson A, Allen E, Thalanany MM, et al. Efficacy and economic assessment of conventional ventilatory support versus extracorporeal membrane oxygenation for severe adult respiratory failure (CESAR): a multicentre randomised controlled trial. *Lancet* 2009; 374:1351-63.
8. Dellinger RP, Levy MM, Rhodes A, Annane D, Gerlach H, Opal SM, et al. Surviving sepsis campaign: international guidelines for management of severe sepsis and septic shock, 2012. *Intensive Care Med* 2013; 39:165-228.
9. Coskun KO, Popov AF, Schmitto JD, Hinz J, Kriebel T, Schoendube FA, et al. Extracorporeal circulation for rewarming in drowning and near-drowning pediatric patients. *Artif Organs* 2010; 34:1026-30.
10. Wang CH, Chou CC, Ko WJ, Lee YC. Rescue a drowning patient by prolonged extracorporeal membrane oxygenation support for 117 days. *Am J Emerg Med* 2010; 28:750.e5-7.
11. Beurtheret S, Mordant P, Paoletti X, Marijon E, Celermajer DS, Léger P, et al. Emergency circulatory support in refractory cardiogenic shock patients in remote institutions: a pilot study (the cardiac-RESCUE program). *Eur Heart J* 2013; 34:112-20.