

MJEM

MEDITERRANEAN JOURNAL OF EMERGENCY MEDICINE

Original Articles

Heat exhaustion in the emergency department should not be confused with other forms of heat related illness

Influential factors on urban and rural response times for emergency ambulances in Qatar

EPP suite à l'actualisation du protocole de prise en charge des syndromes coronariens avec sus décalage du segment ST adapté à un département rural

Case Reports

Sweet syndrome presents with severe SIRS

A Scottish shower

Reducing the trauma burden in the UAE

Successful extracorporeal membrane oxygenation use in acute respiratory distress syndrome after freshwater drowning

Utility of PoCUS in diagnosis of aortic dissection

Cannabinoid Hyperemesis Syndrome with hyperlactatemia

Envenimation. Prise en charge d'une morsure de vipère au retour du Mali

Un syndrome douloureux lombo-abdominal atypique

A SCOTTISH SHOWER: A CASE OF PHLEGMASIACERULEA DUE TO AN AORTOCAVAL FISTULA CAUSED BY AN ABDOMINAL AORTIC ANEURYSM

CAZES N, DEMAISON X, BOUZAD C, VIANT E, PUIDUPIN A. A scottish shower: A case of phlegmasiacerulea due to an aortocaval fistula caused by an abdominal aortic aneurysm. *Med Emergency, MJEM* 2018; 26:22-4.

Key words: abdominal aortic aneurysm, aortocaval fistula, phlegmasiacerulea

ABSTRACT

The abdominal aortic aneurysm is a rare but life-threatening condition. The most-at-risk population is men aged over 50 years, smokers. This pathology is undetectable until the complications become symptomatic but is often diagnosed too late that's why its mortality rate is very important, especially when symptoms are atypical or complications are unusual. We report a rare case of phlegmasiacerulea due to an aortocaval fistula caused by an abdominal aortic aneurysm.

Authors' affiliation:

Correspondent author: Nicolas CAZES, MD

Bataillon de Marins-pompiers de Marseille (BMPM), service médical d'urgence
9 boulevard de Strasbourg,
13233 MARSEILLE cedex 20
joelemorisson@free.fr

Cazes N, MD¹, Demaison X, MD², Bouzad C, MD³, Viant E, MD³, Puidupin A, MD⁴

1. BMPM, Groupement santé, 9 boulevard de Strasbourg, 13233 Marseille
2. Brigade de sapeurs-pompiers de Paris, Service médical d'urgence, 1 place Jules Renard, 75017 Paris
3. Hôpital d'Instruction des Armées Bégin, Service d'Accueil des Urgences, 69 Avenue de Paris, 94160 Saint Mandé
4. Direction générale de la santé, Ministère des affaires sociales et de la santé, 14 avenue Duquesne, 75750 Paris



Dr Nicolas Cazes

Article history / info:

Category: Case report
Received: Dec. 28, 2016
Revised: Jan. 25, 2017
Accepted: Feb. 22, 2017

Conflict of interest statement:

There is no conflict of interest to declare

BACKGROUND

The abdominal aortic aneurysm (AAA) is a rare but life-threatening condition occurring particularly in malesmokers aged over 50 years [1]. The systematic screening of AAA in this most-at-risk population [2;3] and the introduction of endovascular treatment of ruptured AAA in the last decade allowed to decrease the mortality rate [4] of admitted patients to the emergency department (ED) with a ruptured AAA. Nevertheless, the mortality rate of ruptured AAA treated in emergency situations is substantial (ranging from 20 to 60 %) [5;6]. Hence, emergency physicians should know the specific symptomatology and its various complications in order to diagnose this high risk pathology. We present a rare case of a phlegmasia cerulea due to an aortocaval fistula secondary (ACF) to an AAA.

CASE PRESENTATION

We report the case of a 58-year-old man who consulted at the ED for a sudden onset of pain in the right leg. He declared no past medical history except active smoking (20 cigarettes per day during 20 years or 20 packs per year) stopped five years ago. He clearly reported that he felt an intense pain at the inguinal aspect of the right thigh with a sound of crack when he came out of the shower an hour and half earlier. On arrival, his right lower limb was painful (8/10 on the numeric rating scale for pain) and he had difficulty to walk. He confirmed that there was no recent trauma and no previous pain. Vital signs were: afebrile, heart rate of 124 beats per minute and blood pressure of 156/77 mmHg. The physical examination showed a cold, swelling and blue right leg with marbling (**Figure 1**). All arterial pulses (femoral, popliteal and pedal) were found bilaterally. We noted

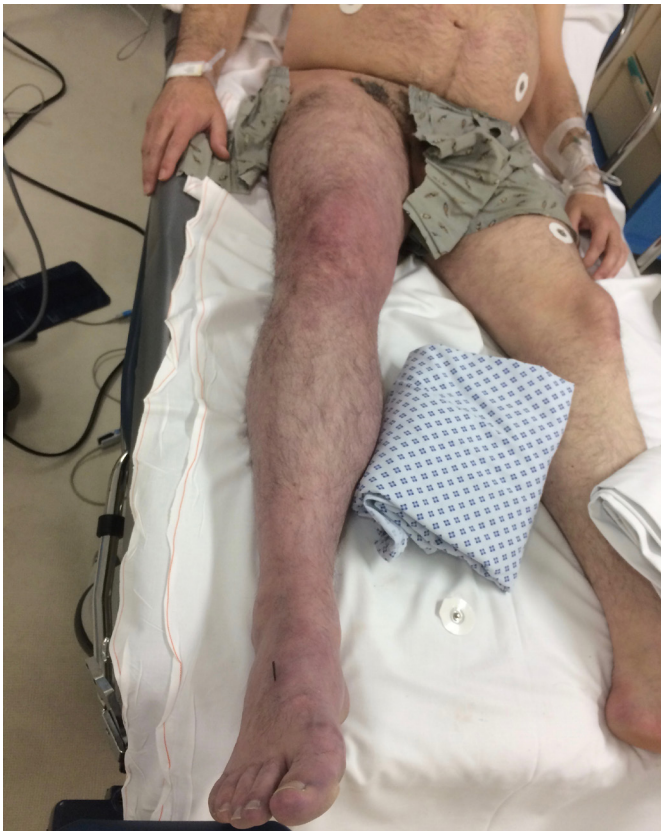

Figure 1: clinical presentation of the cold, swelling and blue right leg with marbling ©NCazes

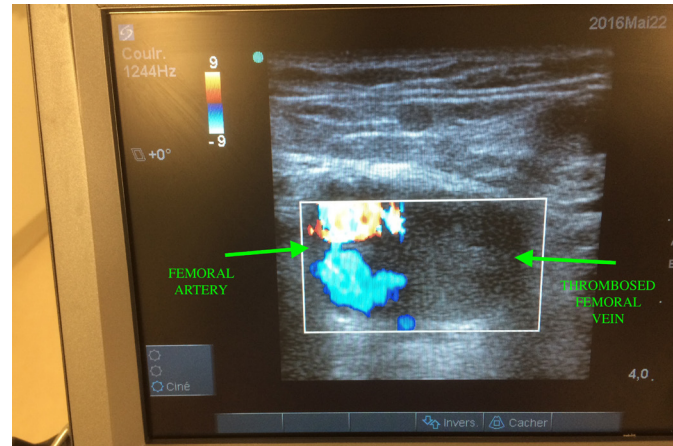


Figure 3: ultrasound image of venous thrombosis and persistent arterial flow ©NCazes

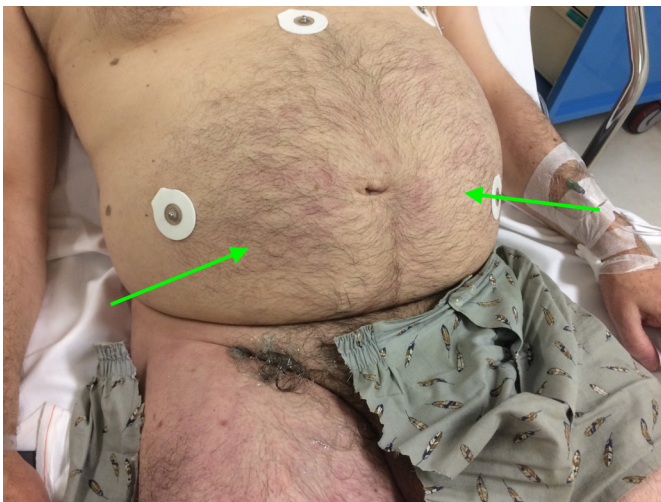


Figure 2: marbling on the abdomen ©NCazes

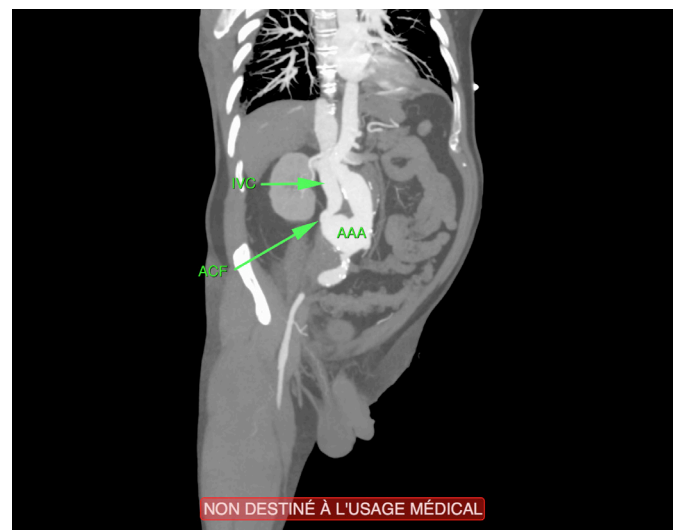


Figure 4: CT-scan image of aorticaval fistula (oblique coronal view) ©NCazes

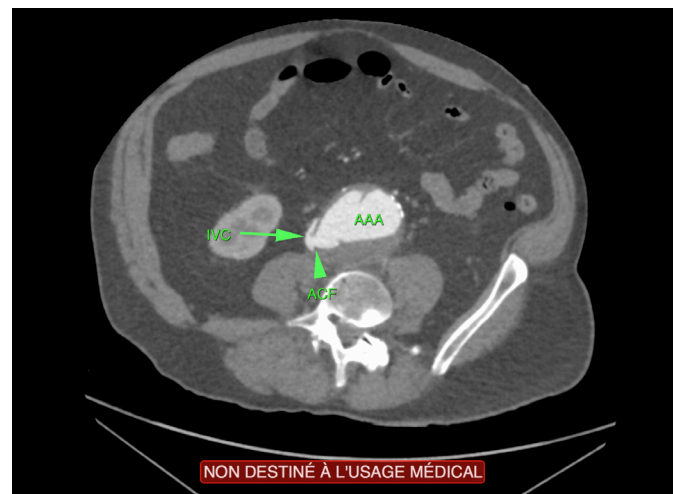


Figure 5: CT-scan image of aorticaval fistula (axial view) ©NCazes

a partial sensitive deficit of the foot up to the knee on the right side and marbling on the abdomen (Figure 2) without pain nor bruit. A vascular bedside ultrasound showed a proximal deep venous thrombosis (to the primitive iliac vein up to the popliteal vein) allowing to evoke the diagnosis of phlegmasia cerulea (Figure 3). We tried to see if the thrombosis concerned the inferior vena cava and discovered fortuitously an AAA. An enhanced thoraco-abdomino-pelvic CT-scan was immediately performed and confirmed a sacciform infra-renal aortic aneurysm of 7 cms diameter, partially thrombosed with ACF (Figures 4 and 5) and a bilateral distal pulmonary embolism. Blood tests showed an increased white blood cell count ($13000.\text{mm}^3$), C-reactive protein (115 mg.L^{-1}), uremia

(9 mmol.L^{-1}), creatinine ($115 \mu\text{mol.L}^{-1}$) and arterial lactate (3 mmol.L^{-1}). The patient was immediately transferred to a vascular surgery team in another hospital to be treated. Until the surgery, we controlled the blood pressure with a continuous intravenous urapidil infusion and an analgesic therapy which combined two continuous intravenous infusions of sufentanyl and ketamine. He had an aorto-bi-iliac bypass to repair the aorta and a patch on the inferior vena cava to close the fistula. After

a five hours successful surgery, a blood loss of three liters and a ten days stay at hospital, the patient has finally totally recovered.

DISCUSSION

AAA disease is a common pathology nowadays in the Western population with a prevalence estimated at 2% to 5% among men aged over 50 years [3;4] and its spontaneous rupture is correlated with a high mortality [4]. The prevalence of ACF in patients with AAA is low, about 2% to 6% [5] but it remains a well-known complication. The typical described clinical presentation (abdominal or lower back pain, pulsatile abdominal mass and abdominal bruit) is in fact not so common (< 50%) [5] and it is more likely to show the association of an abdominal pain, a high-output congestive cardiac failure and a large venous inflow with its complications (swelling and cyanotic lower limb, hematuria, acute renal failure, scrotal edema, priapism, etc.) [6]. We describe an authentic case of phlegmasiacerulea which was the only symptom of ACF due to AAA. This association of pathologies is not common as our review of the literature proves it, with only two similar case found [7;8]. The phlegmasia cerulea, first described by Grégoire in 1938 [9], is an acute and massive deep vein thrombosis which needs an

urgent medical, and sometimes surgical, treatment to avoid necrosis and limb amputation. In our case, the AAA compressing the inferior cava vein caused obstruction of venous outflow which was responsible gradually to a diffuse pre-thrombotic state of the lower limb venous network. The natural evolution of this state allowed to a total and sudden thrombosis of the right common iliac, common femoral and popliteal veins after the migration of a venous embolism. Cinara et al. [10] described a series of 1698 AAA surgically treated among which only 26 cases with ACF. The operative mortality rate of the 26 ACF was 19,2%. Because of the small number of the combination of both phlegmasiacerulea and ACF cases, it doesn't exist data about mortality but it is easily understandable that its management is particularly challenging and mortality rate is very high. Our patient is one of those exceptional cases who had survived.

CONCLUSION

The aortocaval fistula (ACF) is a rare complication of the AAA. Its treatment is associated with a high mortality rate [8] because it is often discovered late. The phlegmasiacerulea belongs to these unusual features which emergency physicians should know.

REFERENCES

1. Lederle FA, Johnson GR, Wilson SE, Chute EP, Littooy FN, Bandyk D, et al. Prevalence and associations of abdominal aortic aneurysm detected through screening. Aneurysm detection and management (ADAM) Veterans Affairs Cooperative Study Group. *Ann Intern Med* 1997; 126:1-9.
2. Moll F, Powell J, Fraedrich G, Verzini F, Haulon S, Waltham M, et al. Management of abdominal aortic aneurysms clinical practice guidelines of the European society for vascular surgery. *Eur J Vasc Endovasc Surg* 2011; Suppl 1:1-58.
3. Beck AW, Sedrakyan A, Mao J, Venermo M, Faizer R, Debus S, et al. International Consortium of Vascular Registries. Variations in abdominal aortic aneurysm care: A report from the International Consortium of Vascular Registries. *Circulation* 2016; 24:1948-58.
4. Schermerhorn ML, Bensley RP, Giles KA, Hurks R, O'malley AJ, Cotterill P, et al. Changes in abdominal aortic aneurysm rupture and short-term mortality, 1995-2008: a retrospective observational study. *Ann Surg* 2012; 256:651-8.
5. Larsson E, Granath F, Swedenborg J, Hultgren R. More patients are treated for nonruptured abdominal aortic aneurysms, but the proportion of women remains unchanged. *J Vasc Surg* 2008; 48:802-7.
6. Ozdemir BA, Karthikesalingam A, Sinha S, Poloniecki JD, Vidal-Diez A, Hinchliffe RJ, et al. Association of hospital structures with mortality from ruptured abdominal aortic aneurysm. *Br J Surg* 2015; 102:516-24.
7. Myers PO, Kalangos A, Terraz S. Ruptured aortic aneurysm masquerading as phlegmasia cerulea. *Am J Emerg Med* 2008; 26:1067.e1-2.
8. Ben Abdallah I, El Batti S, da Costa JB, Julia P, Alsac JM. Phlegmasia cerulea dolens as an unusual presentation of ruptured abdominal aortic aneurysm into the inferior vena cava. *Ann Vasc Surg* 2017; 40:298.e1-4.
9. Grégoire R. La phlébite bleue (phlegmatia caerulea dolens). *Presse Med* 1938; 46:1313-5.
10. Cinara IS, Davidovic LB, Kostic DM, Cvetkovic SD, Jakovljevic NS, Koncar IB. Aorto-caval fistulas: A review of eighteen years experience. *Acta Chir Belg* 2005; 105:616-20.